



**PATIENT**

Bella Ferguson

**SPECIES**

Canine

**BREED**

Labrador Retriever

**SEX**

Female Spayed

**AGE**

8 years

**WEIGHT**

86lbs

**INTERPRETED BY**

Maggie Machen  
 Lamy, DVM, DACVIM  
 (Cardiology)

**IMAGING PERFORMED BY**

Sara Hansen

**HOSPITAL NAME**

Q Street Animal  
 Hospital

**REFERRING VET**

Dr. Hoerauf

**INVOICE**

26213

**DATE**

9/6/22

**PRESENTING CLINICAL SIGNS**

History: Presented for 3 weeks duration of worsening cough, exercise intolerance and poor appetite. No murmur on examination, harsh lung sounds bilaterally. -Current medications Amoxicillin, Baytril, Furosemide.

**RADIOGRAPHIC FINDINGS** \*NOTE: Images submitted for supplemental cardiac information only. Cardiomegaly with evidence of left-sided CHF.

**ELECTROCARDIOGRAPHIC FINDINGS** \*Note: Single lead ECGs are evaluated as a rhythm strip. Morphology/MEA cannot be definitively commented on.

A single lead ECG is available; 50mm/s, 20mm/mV. The average heart rate is 130bpm with a largely regular rhythm. The rhythm appears sinus in origin, although P waves are difficult to visualize throughout. The QRS morphology is positive. No ectopic beats, pauses or dysrhythmias observed.

ECG diagnosis: Normal sinus rhythm.

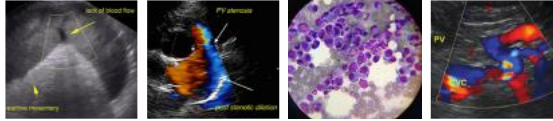
**ECHOCARDIOGRAM FINDINGS**

2D, m-mode, color flow and doppler imaging is available. Severe left ventricular dilation with diminished systolic function and increased sphericity. Decreased LV wall thickness. Increased EPSS. Severe left atrial enlargement. The mitral valve appears mildly thickened, with no obvious prolapse into the left atrial lumen. Moderate eccentric mitral regurgitation. Tricuspid valve appears normal in form and function. Moderate right atrial and ventricular dilation. Mild tricuspid regurgitation. The aortic valve is normal in morphology and mobility. No aortic or pulmonic insufficiency. Decreased RVOT and LVOT velocities. No pericardial or pleural effusion noted. No obvious cardiac tumors.

**CARDIAC CHART**

CANINE CARDIAC PARAMETERS	MR VMAX (m/s)	TR VMAX (m/s)	LA/AO (Boon method)	LA/AO (Heart Base; Swe)	FS (%)	EF (%)	EPSS (cm)
NORMAL PARAMETER	4.5-5.5	<2.7	1.3	<1.6	28-40	40-100	<0.6
PATIENT	NM	NM	NM	2.5	13	28	0.8
CANINE CARDIAC PARAMETERS	HR (BPM)	AV VMAX (m/s)	PV MAX (m/s)	BODY WEIGHT (kg)	LA 2D short axis Base view (cm)	LVIDd Avg; 2D and m-mode short axis (cm)	LVIDs Avg; 2D and m-mode short axis (cm)
NORMAL PARAMETER	50-100	0.7-1.7	0.7-1.6	BELOW	BELOW	BELOW	BELOW
PATIENT	NM	1.3	0.5	39.0	3.9	7.0	6.0
*Normal chamber parameters expressed as a mean value (SD)				3	1.27 (5.3)	2.46 (2.46)	1.36 (5.5)
<b>BODY WEIGHT DEPENDENT PARAMETERS</b>				5	1.40 (4.5)	2.74 (5.2)	1.60 (4.7)
				10	1.50 (3.8)	3.27 (3.5)	2.06 (3.1)
				15	1.83 (2.0)	3.71 (2.4)	2.43 (2.1)
				20	2.02 (1.9)	4.14 (2.2)	2.80 (2.0)

Adapted from June Boon, Veterinary Echocardiography, 1998  
 Rishniw M and Hollis NE, J Vet Intern Med 2000; 14:429-435



**PATIENT**

Bella Ferguson

**SPECIES**

Canine

**BREED**

Labrador Retriever

**SEX**

Female Spayed

**AGE**

8 years

**WEIGHT**

86lbs

**INTERPRETED BY**

Maggie Machen  
Lamy, DVM, DACVIM  
(Cardiology)

**IMAGING PERFORMED BY**

Sara Hansen

**HOSPITAL NAME**

Q Street Animal  
Hospital

**REFERRING VET**

Dr. Hoerauf

**INVOICE**

26213

**DATE**

9/6/22

Hansson et al, Vet Rad and Ultrasound 2002 Bonagura et al. Echocardiography: principles of interpretation, Vet Clin North Am 15:1177, 1995	25	2.18 (2.4)	4.48 (2.9)	3.10 (2.5)
	30	2.33 (3.3)	4.83 (3.9)	3.39 (3.4)
	35	2.48 (4.3)	5.17 (5.0)	3.69 (4.5)
	40	2.62 (5.2)	5.48 (6.1)	3.96 (5.4)
	50	2.88 (7.1)	6.07 (8.3)	4.46 (7.4)

**INTERPRETATION OF THE FINDINGS & FURTHER RECOMMENDATIONS**

Unfortunately, this patient has end-stage cardiomyopathy and systolic dysfunction. This is causing dilation and volume overload of both the left and right heart. Moderate MR is noted, which is suspected to be secondary to annular stretch. The severity of dysfunction and pump failure is marked, and the patient is at exceedingly high risk for decompensating into congestive failure. Patient will always be at risk for right and/or left-sided CHF, development of arrhythmias/syncope and/or sudden death going forward. The ECG is unremarkable with a normal sinus rhythm.

Systolic failure can be primary in nature (DCM) or secondary to taurine deficiency, myocarditis, tachycardia-induced cardiomyopathy, thyroid disease, or infiltrative disease such as lymphoma. In a large breed dog, primary disease is certainly possible; however, consider testing for primary causes that may be treatable. A troponin (cTnI) level can be submitted to further investigate infiltrative/inflammatory contribution (myocarditis). Additionally, a taurine level may be helpful (screen for malabsorption issue), and a thorough diet history given the recent correlation with grain free/boutique brand/exotic ingredient diets. Finally, further systemic evaluation for underlying infiltrative contribution such as neoplasia is also reasonable (abdominal ultrasound, etc.). Regardless of cause, prognosis is poor at this stage in the disease process, with an average survival time of <6 months. The only treatable cause of systolic failure is diet/taurine deficiency, which is uncommon on commercially formulated dog foods. If the diet is of concern, highly recommend immediate diet change and taurine supplement regardless of blood taurine results. Please see the FDA website for more information.

The respiratory signs and chest radiograph findings are suggestive of CHF and continued lifelong cardiac supportive medications are recommended as below. If the breathing worsens or the patient appears unstable, consider hospitalization for stabilization. Cases of systolic failure are at high risk for malignant tachyarrhythmias (such as VT or rapid AF) and sudden death, and this should be expressed to the owner. Activity restriction is advised, and a baseline ECG recommended.

Elective anesthesia is not advised due to exceedingly high risk for complications.

Omega fatty acid supplementation and mild salt restriction may be of some long-term benefit. Monitor for development of a cough, worsening labored breathing, abdominal distention, exercise intolerance or collapse episodes in the future. Monitoring of sleeping breathing rates at home is recommended to assess response to medications and recurrence of CHF in the future.

**PLAN**

Baseline BP is recommended. Consider hospitalization if needed for injectable Lasix, oxygen support, etc. Initiate aldosterone antagonist Spironolactone 1-2mg/kg PO q12h. Institute furosemide 1-2mg/kg PO q12h. Institute Pimobendan 0.3mg/kg PO q12h. Institute taurine 1000mg PO q12h. Diet history/change as discussed.



**PATIENT**

Bella Ferguson

**SPECIES**

Canine

**BREED**

Labrador Retriever

**SEX**

Female Spayed

**AGE**

8 years

**WEIGHT**

86lbs

**INTERPRETED BY**

Maggie Machen Lamy, DVM, DACVIM  
(Cardiology)

**IMAGING PERFORMED BY**

Sara Hansen

**HOSPITAL NAME**

Q Street Animal Hospital

**REFERRING VET**

Dr. Hoerauf

**INVOICE**

26213

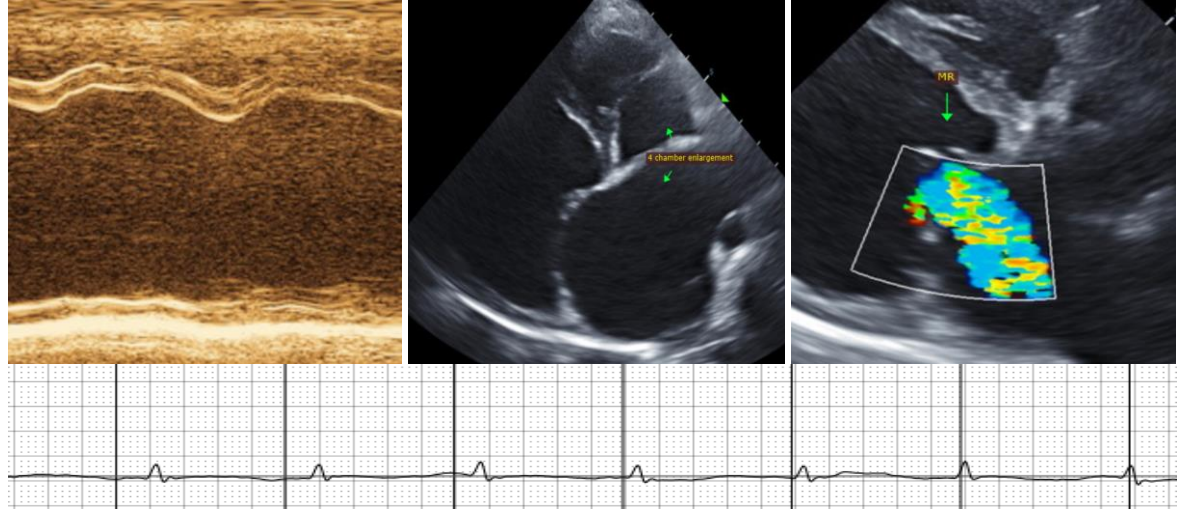
**DATE**

9/6/22

Monitor a renal panel and blood pressure in 1-2 weeks to ensure tolerance. If BP >130mmHg, institute ACEI 0.5mg/kg PO q12h. Consider cTnl, taurine level, AUS as discussed above.

A recheck echocardiogram is recommended in 4-6 months to screen for progression, sooner if clinical issues arise in the interim.

**IMAGES**



The information and recommendations provided are based on the images presented by the referring veterinarian. No evaluation can be communicated regarding pathology that was not visible in the image/video clips provided.

Thank you for this referral. This report was generated using transcription software, and minor dictation errors may be present. If the clinical or image interpretation does not parallel your findings or if I can be of any further assistance, please contact me.

Maggie Machen Lamy, DVM  
Diplomate of the American College of Veterinary Internal Medicine (Cardiology)  
info@sonopath.com